

## **BALLOON KYPHOPLASTY AS A TREATMENT FOR VERTEBRAL COMPRESSION FRACTURES**

*A Technology Assessment*

### **INTRODUCTION**

The California Technology Assessment Forum is requested to review the scientific evidence for the use of balloon kyphoplasty for the treatment of vertebral compression fractures. This review was prompted by the publication of the first randomized controlled trial of balloon kyphoplasty.

### **BACKGROUND**

Vertebral compression fractures are a significant morbidity and mortality related outcome of both primary and secondary osteoporosis.<sup>1-3</sup> Approximately 10 million Americans older than 50 have osteoporosis, with 34 million more at risk, resulting in 1.5 million fragility fractures (spine, hip, forearm) annually.<sup>1</sup> Remaining lifetime risk for diagnosed vertebral fracture is estimated to be 16% for white women over age 50. While osteoporosis is more common among women, and more common among whites, it can and does occur in men and in any race/ethnic group. Most osteoporotic fractures heal within a few weeks or month, but a minority of patients has persistent pain that does not respond to conservative measures. In addition, vertebral fractures due to osteoporosis are associated with a decline in function and mortality, particularly for elderly patients.<sup>2,3</sup> Vertebral compression fractures also occur as a result of trauma,<sup>4</sup> osteolytic metastases<sup>5,6</sup> and from multiple myeloma.<sup>7</sup>

Traditional treatment for patients with vertebral compression fractures is medical management and includes bed rest, analgesics, and bracing. In the 1980's, a percutaneous interventional technique called vertebroplasty, which involves augmentation of vertebral compression fractures with polymethylmethacrylate (PMMA), was developed to treat persistent pain from compression fractures. Vertebroplasty, however, does not attempt to restore the height of the collapsed vertebral body. Vertebroplasty was first used in the United States in the early 1990's and has since become fairly widely used based on observational data only. There are no published randomized controlled trials (RCT) of vertebroplasty. Currently there are two planned/recruitment phase RCTs

of vertebroplasty versus sham procedure to evaluate both the efficacy and potential harm of vertebroplasty for osteoporotic vertebral compression fractures.<sup>8,9</sup>

Kyphoplasty is an even newer technique that involves the introduction of inflatable bone tamps (balloons) into the vertebral body. Once inflated, the bone tamps restore the vertebral body back toward its original height while creating a cavity into which PMMA can be injected under low pressure, potentially reducing the chances of unwanted cement leakage into the spinal canal and adjacent veins. Other theoretical advantages of balloon kyphoplasty are to alleviate pain, to expand the vertebral body and, if possible, to stabilize the spine, that is, to prevent further vertebral collapse and thus possibly prevent kyphosis.<sup>10</sup>

## **TECHNOLOGY ASSESSMENT (TA)**

**TA Criterion 1:           The technology must have final approval from the appropriate government regulatory bodies.**

As a surgical procedure, balloon Kyphoplasty is not subject to FDA clearance. However, an inflatable bone tamp is required to perform the surgery. The Kyphon Inflatable Bone Tamp (Kyphon, Santa Clara, CA) first received FDA 510(ki) clearance in 1998. Subsequent models received FDA 510(k) clearance in 2001 and 2003.

Several device makers have received 510(k) clearance for the bone cement used in the procedure.

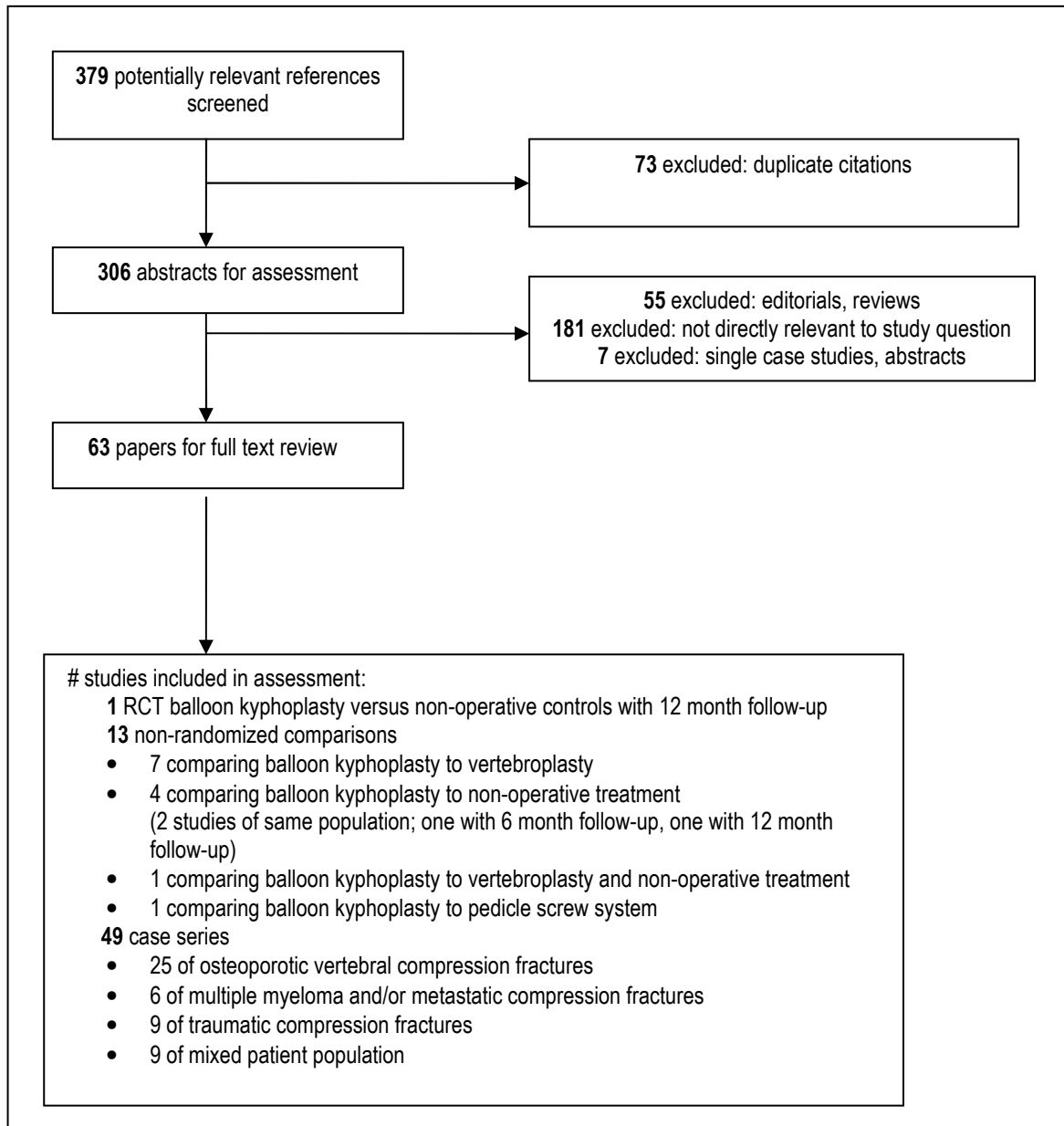
TA Criterion 1 is met.

**TA Criterion 2:           The scientific evidence must permit conclusions concerning the effectiveness of the technology regarding health outcomes.**

The Medline, Embase, and Cochrane clinical trials database, Cochrane reviews database and the Database of Abstracts of Reviews of Effects (DARE) were searched for relevant references through April 2009. (See appendix for search terms) Of 379 potentially relevant citations, we found 63 papers from 62 unique studies to include in this assessment. (See Figure below for study selection details) Of these 62 studies, one was a randomized controlled trial of balloon kyphoplasty

versus non-surgical usual care,<sup>11</sup> 13 were non-randomized comparison studies,<sup>12-24</sup> and 49 were case series.<sup>25-73</sup>

**Figure 1: Study Selection**



Level of Evidence: 1, 3, 5  
 TA Criterion 2 is met.

**TA Criterion 3: The technology must improve net health outcomes.**

*Case Series*

Of the 49 case series, 25 were focused on a population with osteoporosis as the etiology of their vertebral compression fractures, six on a population with either multiple myeloma or metastatic cancer as the etiology, nine on a population with trauma as the etiology, and eight on a population with a mixture of the above etiologies. The series of patients with osteoporotic vertebral compression fractures ranged in size from three patients to 222, and most studies fewer than 100 patients. They also varied in whether they studied patients with acute (<3 months) or chronic (>3 months) fractures, and in whether the patients had primary or secondary (e.g. due to chronic steroid use) osteoporosis. The largest case series of 222 patients with 360 osteoporotic vertebral compression fractures reported immediate complete pain relief for 78% and partial pain relief for another 11% of patients, moderate increase in vertebral height (mean height restoration of 30%) and new adjacent or remote fractures in 12% of patients.<sup>53</sup> Eleven percent of fractures treated with kyphoplasty in this series had cement extravasation, which resulted in a painful radiculopathy for one patient. Overall the authors reported ten medical and three surgical complications ranging from need for surgical debridement to a spinal abscess in a patient on prednisone who ultimately died of a heart attack. The next largest series of 155 patients with 214 fractures (all but one had osteoporosis) treated at 19 different clinical sites reported two year data on 100 of their enrollees,<sup>41</sup> and found that at least for this subset of patients both pain reduction and improvement in function were immediate and sustained over the two-year period. Refracture rates (61% in adjacent vertebrae) were 20% at one year and 23% at two years. These authors also report a 10% cement extravasation rate, all of which were asymptomatic in this series. Other complications included one perioperative episode of paroxysmal supraventricular tachycardia, one patient with three rib fractures related to being moved intraoperatively and one myocardial infarction 28 days post-operatively.

The largest case series, reported this year by McArthur et al,<sup>58</sup> followed 555 patients with 1150 vertebral fractures of mixed etiology post-kyphoplasty for 30 days to assess complications. These investigators found cement leakage in 38 vertebrae, a single case with resultant permanent leg neurologic deficit, two cases with temporary neurologic deficits, two cases of hemorrhage, and one

pulmonary embolism which was asymptomatic. Case series of patients with traumatic compression fractures only have been small (ranging from 4 to 39) and show similar observations to those studies of patients with osteoporosis, including rapid improvement in both pain and vertebral height. Several of these small case series used calcium phosphate cement rather than the PMMA used in studies of osteoporotic and pathologic fractures.

The case series of patients with pathologic compression fractures from osteolytic metastases or multiple myeloma are also small, ranging in size from three to 65 participants. The largest of these,<sup>65</sup> focused on 65 patients with metastatic fractures, with two-year follow-up on 41 patients, and they observed a substantial decrease in visual analogue pain scale (0-100 range) from 83 to 33 post-operatively, which was sustained (32) at two-years. While vertebral body height was significantly increased post-operatively, there was a gradual decrease from six months on back to baseline at two-years. Similar to series of other populations, these authors report a 12% cement extravasation rate, and an 8% incident fracture rate in adjacent vertebrae.

#### *Non-Randomized Comparison Studies*

Of the 13 non-randomized comparison studies, four compared balloon kyphoplasty to non-operative care.<sup>15, 18, 22, 23</sup> Two of these were of the same patients with chronic (>12 month) osteoporotic fractures – one with six-month follow-up,<sup>18</sup> and the other with one-year follow-up<sup>15</sup> – comparing 40 patients who underwent balloon kyphoplasty to 20 similar, unmatched controls. These authors observed a significantly increased vertebral height post-operatively which was sustained at six and 12 months, sustained decrease in pain at six and 12 months for the balloon kyphoplasty group compared to controls, and improvement in mobility post-operatively, which was different from controls at six months, but no difference at 12 months. There was a 17.5% new fracture rate in the kyphoplasty group and a 50% new fracture rate in the control group; there was no statistical difference in the number of new fractures in adjacent vertebrae to the index fracture in either group. A third study of 40 patients with acute painful traumatic vertebral fractures observed improved pain, mobility and vertebral body height for patients in the balloon kyphoplasty group compared to non-operative controls at one and three months; however, the only sustained difference at 12 months was for vertebral body height.<sup>22</sup> These authors observed a high rate (45%)

of asymptomatic cement extravasation (calcium phosphate cement) compared with other studies. The fourth study confirmed that increases in vertebral body height were greater from balloon kyphoplasty than that which could be achieved from positioning maneuver alone.<sup>23</sup>

There are seven studies which compare balloon kyphoplasty to vertebroplasty, which range in size from 21 to 98. These small non-randomized studies have shown mixed results in terms of which procedure either produces more benefit or less harm. For example, a study of 34 patients with multiple myeloma showed equal improvements in pain post-operatively, but moderately better results for kyphoplasty at six and twelve months.<sup>19</sup> Similarly, a study of 51 patients with chronic fractures demonstrated long-lasting (up to two years) decrease in pain for the kyphoplasty group only; neither group demonstrated significantly decreased pain from baseline at two years).<sup>16</sup> By contrast, another study of 36 patients showed comparable postoperative pain results for both procedures, but more asymptomatic cement extravasation and more new adjacent level fractures for the kyphoplasty group.<sup>14</sup> Other studies demonstrated no difference between the two procedures, except that kyphoplasty resulted in better restoration of vertebral height.<sup>12, 24</sup> Whereas, another study found no difference in vertebral height restoration and more asymptomatic cement extravasation with kyphoplasty.<sup>17</sup> Lastly, a study of 38 elderly women with osteoporotic compression fractures found an immediate improvement on vital capacity, forced vital capacity and maximum voluntary ventilation for both interventions, but only the improved vital capacity was sustained at three-months. Kyphoplasty improved vital capacity more than vertebroplasty.<sup>13</sup>

An additional single study assessed the impact of the intervention on subsequent vertebral compression fractures in 48 treatment (vertebroplasty or kyphoplasty) and 164 controls with similar conditions and incident fractures during the study period, and found that the intervention group had an almost seven-fold increased odds of a new fracture within 90 days and a three-fold increased odds of a new fracture within one-year compared to controls.<sup>21</sup> However, the investigators only matched patients on age, and they did not develop a propensity score to account for possible selection bias for the procedure.

Lastly, a study of 86 patients compared results for those who underwent either kyphoplasty or pedicle screw system to treat vertebral compression fractures.<sup>20</sup> Patients were matched by age,

gender, bone density, vertebral height and visual analogue pain scale at baseline. This study found no difference in post-operative vertebral height, but did find significantly improved pain scores, shorter operation time and less blood loss for the kyphoplasty group.

### *Randomized Controlled Trials*

The above case series and non-randomized comparison studies are suggestive that balloon kyphoplasty is an effective treatment for vertebral compression fractures of various etiologies. However, there is clearly some risk to the procedure, and the benefit compared to other treatment options – particularly non-operative care, other types of minimally invasive surgical intervention (e.g. vertebroplasty) – cannot be determined from case series and small non-randomized comparison studies which are susceptible to various biases (e.g. bias by indication, selection bias, recall bias), confounding, and lack of power to detect differences in outcome or harm. RCTs are required to address these issues.

To date, there is only one RCT of balloon kyphoplasty, published this year in Lancet.<sup>11</sup> See Table 1 below for details of the patient population, study design, and pre-specified outcomes. Of note, this study compared balloon kyphoplasty with PMMA to non-surgical care at 21 sites in 18 countries. Non-surgical usual back care was not standardized, but included some combination of walking aids, back braces, physical therapy, and opioid and non-opioid analgesia. There was no sham-comparison group, and there was no blinding of either investigators or patients. While the investigators intended to include patients with vertebral fractures due to multiple myeloma or osteolytic metastases, the vast majority of enrollees had primary osteoporosis; only eight participants had secondary osteoporosis, and only four had pathologic fractures. Additionally, it is important to note that this trial studied patients with recent (<3 month) fractures, with an average fracture age of five to seven weeks.

The study was well-powered for the primary outcome of baseline to one month change in short-form-36 (SF-36) physical component summary (PCS) scale by treatment group. The SF-36 is a widely used, validated measure of quality of life, with a standardized norm mean set at 50.<sup>74</sup> Although not completely established, there is some indication that an improvement of five points is a clinically meaningful improvement.<sup>75</sup> In addition, the investigators included clinically meaningful

secondary outcomes, including self-rated back pain on a 0-10 scale, and restricted activity days and bed rest because of back pain in previous 14 days. There does not appear to have been independent adjudication of either outcomes or adverse events. The study was funded by Medtronic LLC.

**Table 1.** Description of the one Randomized Controlled Trial of Balloon Kyphoplasty for Vertebral Compression Fractures.<sup>11</sup> (Wardlaw et al, 2009)

<b><u>Patient Population</u></b>	300 participants enrolled & randomized 149 balloon kyphoplasty / 124 completed 12 month follow-up 151 non-surgical care control group / 111 completed 12 month follow-up  <table border="1" style="width: 100%; border-collapse: collapse;"> <thead> <tr> <th style="text-align: left;">Baseline Characteristics</th> <th style="text-align: center;">Kyphoplasty</th> <th style="text-align: center;">Control</th> </tr> </thead> <tbody> <tr> <td>Mean age</td> <td style="text-align: center;">72 yrs</td> <td style="text-align: center;">74 yrs</td> </tr> <tr> <td>Female</td> <td style="text-align: center;">77%</td> <td style="text-align: center;">77%</td> </tr> <tr> <td>Primary osteoporosis</td> <td style="text-align: center;">97%</td> <td style="text-align: center;">95%</td> </tr> <tr> <td>Secondary osteoporosis</td> <td style="text-align: center;">1%</td> <td style="text-align: center;">4%</td> </tr> <tr> <td>Multiple myeloma/met</td> <td style="text-align: center;">1%</td> <td style="text-align: center;">1%</td> </tr> <tr> <td>Bisphosphonate use</td> <td style="text-align: center;">33%</td> <td style="text-align: center;">32%</td> </tr> <tr> <td>Current Steroid use</td> <td style="text-align: center;">17%</td> <td style="text-align: center;">17%</td> </tr> <tr> <td>Mean age of treated fracture</td> <td style="text-align: center;">5.6 wks</td> <td style="text-align: center;">6.4wks</td> </tr> </tbody> </table>	Baseline Characteristics	Kyphoplasty	Control	Mean age	72 yrs	74 yrs	Female	77%	77%	Primary osteoporosis	97%	95%	Secondary osteoporosis	1%	4%	Multiple myeloma/met	1%	1%	Bisphosphonate use	33%	32%	Current Steroid use	17%	17%	Mean age of treated fracture	5.6 wks	6.4wks
Baseline Characteristics	Kyphoplasty	Control																										
Mean age	72 yrs	74 yrs																										
Female	77%	77%																										
Primary osteoporosis	97%	95%																										
Secondary osteoporosis	1%	4%																										
Multiple myeloma/met	1%	1%																										
Bisphosphonate use	33%	32%																										
Current Steroid use	17%	17%																										
Mean age of treated fracture	5.6 wks	6.4wks																										
<b><u>Study Design</u></b>	Randomized Control Trial No blinding / no sham surgery Randomization stratified by sex, etiology of fracture, current treatment with steroids, any bisphosphonate treatment in prior 12 months 21 clinical enrollment sites in eight countries Intention to treat analysis																											
<b><u>Inclusion criteria:</u></b>	1) 1-3 vertebral fractures from T5-L5 2) at least 1 fracture required to have associated edema by magnetic resonance imaging (MRI) 3) at least 1 fracture required to have at least 15% loss of height 4) additional fractures allowed if they also have edema by MRI and ≥15% height loss 5) etiology of fracture: primary or secondary osteoporosis, multiple myeloma, osteolytic metastatic tumor 6) back pain of ≥4 (0-10 scale)																											
<b><u>Exclusion criteria:</u></b>	1) <21 years old 2) chronic fractures (estimated >3 months) 3) pedicle fracture 4) previous vertebroplasty 5) neurologic deficit 6) radicular pain 4) spinal cord compression or canal narrowing 5) taking uninteruptable anticoagulation therapy 6) allergies to kyphoplasty materials																											

	<p>7) contraindication to MRI              8) dementia              9) unable to walk prior to fracture              10) osteoblastic metastases              11) high energy trauma</p>
<p><b><u>Treatment</u></b></p>	<p><b><u>Intervention</u></b>              Usual care plus balloon kyphoplasty at 1-3 vertebral levels from T5-L5              Medtronic Spine: introducer instruments, inflatable bone tamps, PMMA, delivery device              Approach varied according to clinical practice at enrollment site: bilateral, transpedicular, extrapedicular</p> <p><b><u>Control: usual care</u></b>              All participants received standard practice at enrollment site, including: analgesics, bed rest, back braces, physical therapy, rehabilitation program, walking aids</p>
<p><b><u>Outcomes</u></b></p>	<p><b><u>Primary Outcome</u></b>              Baseline to 1 month change in short-form-36 (SF-36) PCS scale by treatment group</p> <p>Study powered to detect 0.5 SD for 1-month difference; 80% power with two-sided <math>\alpha</math> of 5% (75 participants per group).</p> <p><b><u>Secondary Outcomes at 1, 3, 6, 12 months</u></b>              SF-36 subscales              0-1 point EuroQol-5D (EQ-5D) quality of life questionnaire              Self-rated back pain on 0-10 scale              Back function by 0-24 point Roland-Morris scale              Restricted activity days and bed rest because of back pain in previous 14 days</p> <p>At 5-10 days after either surgery or randomization (controls)              Back pain (0-10)              Analgesic use</p>
<p><b><u>Adverse Events</u></b></p>	<p>Adverse events &amp; serious adverse events reported &amp; reviewed by representative of the device manufacturer and adjudicated as related to device or procedure.              No independent adjudication of adverse events</p> <p>Independent review by 2 radiologists (not blinded to treatment due to radio-opaque cement) of baseline, 3 month and 12 month standing lateral spinal radiographs;</p> <p>Deformity classified as new or worsening fracture if deformity increased by <math>\geq 1</math> Genant grade (normal= grade 0; mild = grade 1 or 20-25%; moderate = grade 2 or 25-40%; severe = grade 3 or &gt;40%)</p>

Notably, this study did find a significant improvement in the one-month mean score on the SF-36 PCS scale for the kyphoplasty group compared to the non-operative controls. (See Table 2 below) This difference declined over the subsequent months, and there was no difference between groups at 12 months as the control group also had improvement. It appears from the secondary outcome results that the kyphoplasty group sustained significant improvements over the study period compared to controls in the majority of the PCS subscales (body pain, role physical, vitality, social function), this was not true for the physical function subscale. Similarly, all of the secondary outcomes had significantly greater improvement for the kyphoplasty group, most sustained through six months, but only sustained the differences at 12 months. Again, both groups showed substantial clinical improvement on all secondary outcomes at 12 months. Notably, for the clinically important outcomes of self-reported pain, analgesic use and days of disability, while there was little to no difference between groups at 12 months, the kyphoplasty group attained the majority of their improvement quickly and sustained this over the course of the year, and the control group took six to 12 months to catch-up. It is important to note that the lack of blinding in this RCT leads to somewhat less confidence about the true magnitude of the subjective quality of life outcomes.

Both groups had a high rate of subsequent fractures over the course of the year (33% in the kyphoplasty group and 25% in the control group) despite high rates of bisphosphonate use. While this was not statistically different, the study was not powered to detect a difference in fracture rates. Consistent with previous observational studies, the kyphoplasty group did have significant amounts of cement extravasation; however, this was asymptomatic in all cases in this study. Other significant clinical events (myocardial infarction, pulmonary embolus) occurred beyond the immediate 30-day post-operative period and so were not attributed to the procedure.

**Table 2.** Results of the one Randomized Controlled Trial of Balloon Kyphoplasty for Vertebral Compression Fractures.<sup>11</sup> (Wardlaw et al, 2009)

OUTCOME	RESULTS	COMMENTS
<p><u>Primary Outcome</u> Baseline to 1 month change in SF-36 PCS scale by treatment group</p>	<p>Mean improvement in SF-36 PCS 5.2 points greater in kyphoplasty group than in control group (95% CI 2.9-7.4; p&lt;.001)</p>	<p>No difference in baseline scores between groups.  Difference declined at each subsequent visit, remained statistically significantly different at 3 and 6 months. No difference at 12 months.</p>
<p><u>Secondary Outcomes at 1, 3, 6, 12 months</u>  SF-36 subscales averaged 12-month differences  0-1 point EQ-5D quality of life questionnaire  Back function by 0-24 point Roland-Morris scale  Restricted activity days and bed rest because of back pain in previous 14 days  <u>At 5-10 days after either surgery or randomization (controls)</u></p>	<p>Body pain: 9.2 points improvement kyphoplasty vs. controls (p=.0008)</p> <p>Role physical: 12.5 points improvement kyphoplasty vs. controls (p.0016)</p> <p>Vitality 5.2 points improvement kyphoplasty vs. controls (p=.039)</p> <p>Social function: 11.4 point improvement kyphoplasty vs. controls (p=.0026)</p> <p>Physical function: at 1-month 9.3 points improvement kyphoplasty vs. controls (p=.008); at 12-months 1.9 points improvement (p=.6)</p> <p>1-month mean improvement in EQ-5D 0.18 points greater in kyphoplasty group than in control group (p=.0003) 12-month 0.12 points greater (p=.025)</p> <p>1-month mean improvement in Roland-Morris 4.0 points greater in kyphoplasty group than in control group (p&lt;.0001); 12-month 2.6 points greater (p=.0012)</p> <p>1 month mean number of restricted activity days/2 weeks 2.9 fewer in kyphoplasty group than in control group (p=.0004); no difference at 12 months</p> <p>1 week mean pain score 2.2 points less</p>	<p>No significant difference between groups at baseline for any secondary measure.  SF-36 subscales: no treatment-time interaction over 12 months for any subscale except for physical function which did have a significant interaction (p=.038), thus 1-month and 12-month results reported.  All remaining secondary outcomes with significant improvement for kyphoplasty group compared to controls at 3 and 6 months as well unless otherwise noted (e.g. for opioid analgesic use).</p>

<p>Back pain (0-10)</p> <p>Opioid analgesic use</p>	<p>in kyphoplasty group than in control group (p&lt;.0001); 12 month mean 0.9 points less (p=.0034)</p> <p>1 month, 3 month percentage of patients taking opioid analgesics decreased more in kyphoplasty group compared to controls (p=.009; .002 respectively. Difference not significant at 6 or 12 months</p>	
<p><u>Adverse Outcomes</u></p> <p>New or worsening radiographic vertebral fractures at 12 months</p> <p>Adverse events</p>  <p>Cement Extravasation</p>	<p>Kyphoplasty group: 38/115 (33%) Control group: 24/95 (25%) p=.22</p> <p>Kyphoplasty group non-perioperative events (≥46 days post-op) Myocardial Infarction N=5 Pulmonary embolism N=3</p> <p>Kyphoplasty group perioperative events Soft tissue hematoma at surgical site N=1 Urinary tract infection requiring intervention N=1</p> <p>51/188 (27%) treated vertebrae (48 patients) – all asymptomatic One foraminal leakage No leakage to spinal canal No cement emboli</p>	<p>Available data for at least seven vertebrae at both baseline and 12 months on only 115 kyphoplasty participants and 95 control participants</p> <p>Study not powered to detect differences in fractures between the two groups</p> <p>Fractures occurred in setting of high rates of bisphosphonate use in both groups (at 12 months: 79% kyphoplasty group, 76% control group)</p>

TA Criterion 3 is met for recent osteoporotic vertebral compression fractures.

TA Criterion 3 is not met for chronic osteoporotic, pathologic or traumatic vertebral compression fractures.

**TA Criterion 4:           The technology must be as beneficial as any established alternatives.**

The primary established alternative for osteoporotic vertebral compression fractures is conservative medical management. This can include bracing, non-opioid and opioid analgesics, and physical therapy.<sup>76</sup> As noted in the assessment above of the RCT by Wardlaw et al, the control group received usual care medical management provided by each clinical site. Because TA Criterion 3 was not met for chronic osteoporotic, pathologic or traumatic vertebral compression fractures, TA Criterion 4 cannot be met for these types of fractures.

TA Criterion 4 is met for recent osteoporotic vertebral compression fractures.

TA Criterion 4 is not met for chronic osteoporotic, pathologic or traumatic vertebral compression fractures.

**TA Criterion 5:           The improvement must be attainable outside of the investigational setting.**

The Wardlaw et al RCT was conducted in 21 clinical sites in 18 countries. The individual balloon kyphoplasty technique as well as the control group's medical management was conducted according to the clinical practice at each site.

TA Criterion 5 is met for recent osteoporotic vertebral compression fractures.

TA Criterion 5 is not met for chronic osteoporotic, pathologic or traumatic vertebral compression fractures.

## **CONCLUSION**

In summary, it appears from the results of the single RCT that balloon kyphoplasty does achieve rapid and sustained improvements in pain and function for patients with new (<3 month old) osteoporotic compression fractures which have been confirmed for both location and age on MRI; however, the majority of these same improvements are achieved after a year for patients receiving

usual back care. Although there were no clinically significant adverse outcomes clearly related to kyphoplasty in this study, it is clear from the bulk of the observational literature that cement leakage can in some cases lead to neurologic symptoms, and that there may be an increased rate of subsequent fractures, particularly in adjacent vertebrae. Pulmonary embolus remains a significant theoretical concern; in a recent study of vertebroplasty, investigators obtained post-operative chest CT scans to assess for pulmonary cement emboli and found them in 23% of cases.<sup>77</sup> Pulmonary cement embolism was associated with cement leakage in the inferior vena cava. Thankfully, the literature supports the conclusion that the vast majority of these emboli remain asymptomatic and presumably clinically non-significant. It is unclear how the different technique used in balloon kyphoplasty impacts this outcome as a similar study has not been conducted after kyphoplasty. Thus, individuals considering balloon kyphoplasty for a recent osteoporotic vertebral compression fracture and their physicians should carefully weigh the benefits of early reduction in pain and improvement in physical function with the small but real possibility of an adverse event. In addition, because the mean age of the fractures in the RCT was 5-6 weeks, it is important that patients have a trial of initial conservative treatment prior embarking on invasive treatment which does carry some risk.

While balloon kyphoplasty appears promising for traumatic and pathologic vertebral compression fractures, comparative studies have been underpowered and there are no RCTs with these populations. For pathologic fractures, it would be important to compare to radiation therapy alone and to assess whether combined therapy would have additional benefit. For traumatic fractures, larger randomized studies, possibly using different cement mixtures, are needed.

#### **DRAFT RECOMMENDATION**

- It is recommended that balloon kyphoplasty with PMMA *meets* CTAF criteria 1-5 for safety, effectiveness and improvement in health outcomes for the treatment of recent (<3 month old) osteoporotic vertebral compression fractures confirmed by MRI.

- It is further recommended that balloon kyphoplasty *does not meet* CTAF criteria 3-5 for safety, effectiveness and improvement in health outcomes for the treatment of chronic (>3 month old) osteoporotic, traumatic, or pathologic vertebral compression fractures.

**June 17, 2009**

This is a first assessment of this technology by the California Technology Assessment Forum

## RECOMMENDATIONS OF OTHERS

### **Blue Cross Blue Shield Association (BCBSA)**

In 2008 the BCBSA Technology Evaluation Center (TEC) conducted an assessment of this technology and found that based on the evidence, Kyphoplasty did not meet TEC criteria.

### **Centers for Medicare and Medicaid Services (CMS)**

CMS provides billing guidance for the Kyphoplasty procedure. In the absence of a National Coverage Decision (NCD) a Local Coverage Decision (LCD) is in place for California through the local carrier effective 8/2008.

### **California Orthopaedic Association (COA)**

The COA has been invited to provide an opinion regarding this technology and to have a representative at the meeting to provide testimony and engage in discussion.

### **California Association of Neurological Surgeons (CANS)**

CANS has been invited to provide an opinion regarding this technology and to have a representative at the meeting to provide testimony and engage in discussion.

### **National Institute for Health and Clinical Excellence (NICE)**

A guidance document is available at: <http://www.nice.org.uk/nicemedia/pdf/IPG166A4Updated.pdf>. The document states that "Current evidence on the safety and efficacy of balloon Kyphoplasty for vertebral compression fractures appears adequate to support the use of this procedure provided that normal arrangements are in place for consent, audit and clinical governance" Please see the document for additional recommendations etc.

**ABBREVIATIONS USED IN THIS REVIEW**

PMMA	Polymethylmethacrylate
RCT	Randomized controlled trials
DARE	Database of Abstracts of Reviews of Effects
SF-36	Short form 36
PCS	Physical component summary
MRI	Magnetic resonance imaging
EQ-5D	EuroQol-5D

**REFERENCES:**

1. Holroyd C, Cooper C, Dennison E. Epidemiology of osteoporosis. *Best Pract Res Clin Endocrinol Metab.* Oct 2008;22(5):671-685.
2. Old JL, Calvert M. Vertebral compression fractures in the elderly. *Am Fam Physician.* Jan 1 2004;69(1):111-116.
3. Truumees E. Medical consequences of osteoporotic vertebral compression fractures. *Instr Course Lect.* 2003;52:551-558.
4. Hanley EN, Jr., Eskay ML. Thoracic spine fractures. *Orthopedics.* May 1989;12(5):689-696.
5. Clark JC, Dass CR, Choong PF. Current and future treatments of bone metastases. *Expert Opin Emerg Drugs.* Dec 2008;13(4):609-627.
6. Vassiliou V, Kardamakis D. The management of metastatic bone disease with the combination of bisphosphonates and radiotherapy: from theory to clinical practice. *Anticancer Agents Med Chem.* Mar 2009;9(3):326-335.
7. Angtuaco EJ, Fassas AB, Walker R, Sethi R, Barlogie B. Multiple myeloma: clinical review and diagnostic imaging. *Radiology.* Apr 2004;231(1):11-23.
8. Buchbinder R, Osborne RH, Ebeling PR, et al. Efficacy and safety of vertebroplasty for treatment of painful osteoporotic vertebral fractures: a randomised controlled trial [ACTRN012605000079640]. *BMC Musculoskelet Disord.* 2008;9:156.
9. Gray LA, Jarvik JG, Heagerty PJ, et al. INvestigational Vertebroplasty Efficacy and Safety Trial (INVEST): a randomized controlled trial of percutaneous vertebroplasty. *BMC Musculoskelet Disord.* 2007;8:126.
10. Pateder DB, Khanna AJ, Lieberman IH. Vertebroplasty and Kyphoplasty for the Management of Osteoporotic Vertebral Compression Fractures. *Orthopedic Clinics of North America.* 2007;38(3):409-418.
11. Wardlaw D, Cummings SR, Van Meirhaeghe J, et al. Efficacy and safety of balloon kyphoplasty compared with non-surgical care for vertebral compression fracture (FREE): a randomised controlled trial. *The Lancet.* 2009;373(9668):1016-1024.
12. De Negri P, Tirri T, Paternoster G, Modano P. Treatment of painful osteoporotic or traumatic vertebral compression fractures by percutaneous vertebral augmentation procedures: A nonrandomized comparison between vertebroplasty and kyphoplasty. *Clinical Journal of Pain.* 2007;23(5):425-430.

13. Dong R, Chen L, Gu Y, et al. Improvement in respiratory function after vertebroplasty and kyphoplasty. *Int Orthop*. Nov 7 2008.
14. Frankel BM, Monroe T, Wang C. Percutaneous vertebral augmentation: an elevation in adjacent-level fracture risk in kyphoplasty as compared with vertebroplasty. *Spine Journal*. 2007;7(5):575-582.
15. Grafe IA, Da Fonseca K, Hillmeier J, et al. Reduction of pain and fracture incidence after kyphoplasty: 1-year outcomes of a prospective controlled trial of patients with primary osteoporosis. *Osteoporosis international : a journal established as result of cooperation between the European Foundation for Osteoporosis and the National Osteoporosis Foundation of the USA*; 2005:2005-2012.
16. Grohs JG, Matzner M, Trieb K, Krepler P. Minimal invasive stabilization of osteoporotic vertebral fractures: A prospective nonrandomized comparison of vertebroplasty and balloon kyphoplasty. *Journal of Spinal Disorders and Techniques*. 2005;18(3):238-242.
17. Hiwatashi A, Westesson PL, Yoshiura T, et al. Kyphoplasty and vertebroplasty produce the same degree of height restoration. *AJNR Am J Neuroradiol*. Apr 2009;30(4):669-673.
18. Kasperk C, Hillmeier J, Noldge G, et al. Treatment of painful vertebral fractures by kyphoplasty in patients with primary osteoporosis: A prospective nonrandomized controlled study. *Journal of Bone and Mineral Research*. 2005;20(4):604-612.
19. Kose KC, Cebesoy O, Akan B, Altinel L, Dincer D, Yazar T. Functional results of vertebral augmentation techniques in pathological vertebral fractures of myelomatous patients. *Journal of the National Medical Association*. 2006;98(10):1654-1658.
20. Ming JH, Zhou JL, Zhou PH, Zhou JP. Comparison of therapeutic effect between percutaneous kyphoplasty and pedicle screw system on vertebral compression fracture. *Chin J Traumatol*. Feb 2007;10(1):40-43.
21. Mudano AS, Bian J, Cope JU, et al. Vertebroplasty and kyphoplasty are associated with an increased risk of secondary vertebral compression fractures: A population-based cohort study. *Osteoporosis International*. 2009;20(5):819-826.
22. Schmelzer-Schmied N, Cartens C, Meeder PJ, Dafonseca K. Comparison of kyphoplasty with use of a calcium phosphate cement and non-operative therapy in patients with traumatic non-osteoporotic vertebral fractures. *Eur Spine J*. Jan 23 2009.
23. Shindle MK, Gardner MJ, Koob J, Bukata S, Cabin JA, Lane JM. Vertebral height restoration in osteoporotic compression fractures: Kyphoplasty balloon tamp is superior to postural correction alone. *Osteoporosis International*. 2006;17(12):1815-1819.

24. Zhou JL, Liu SQ, Ming JH, Peng H, Qiu B. Comparison of therapeutic effect between percutaneous vertebroplasty and kyphoplasty on vertebral compression fracture. *Chinese Journal of Traumatology - English Edition*. 2008;11(1):42-44.
25. Acosta Jr FL, Aryan HE, Taylor WR, Ames CP. Kyphoplasty-augmented short-segment pedicle screw fixation of traumatic lumbar burst fractures: initial clinical experience and literature review. *Neurosurgical focus [electronic resource]*. 2005;18(3):e9.
26. Afzal S, Akbar S, Dhar SA. Short segment pedicle screw instrumentation and augmentation vertebroplasty in lumbar burst fractures: an experience. *Eur Spine J*. Mar 2008;17(3):336-341.
27. Atalay B, Caner H, Gokce C, Altinors N. Kyphoplasty: 2 years of experience in a neurosurgery department. *Surg Neurol*. 2005;64 Suppl 2:S72-76.
28. Becker S, Garoscio M, Meissner J, Tuschel A, Ogon M. Is there an indication for prophylactic balloon kyphoplasty? A pilot study. *Clinical orthopaedics and related research*; 2007:83-89.
29. Berlemann U, Franz T, Orlor R, Heini PF. Kyphoplasty for treatment of osteoporotic vertebral fractures: A prospective non-randomized study. *European Spine Journal*. 2004;13(6):496-501.
30. Carbognin G, Sandri A, Girardi V, et al. Treatment of type-A3 amyelic thoracolumbar fractures (burst fractures) with kyphoplasty: initial experience. *Radiol Med*. Feb 2009;114(1):133-140.
31. Chung HJ, Chung KJ, Yoon HS, Kwon IH. Comparative study of balloon kyphoplasty with unilateral versus bilateral approach in osteoporotic vertebral compression fractures. *Int Orthop*. Dec 2008;32(6):817-820.
32. Costa F, Ortolina A, Cardia A, et al. Efficacy of treatment with percutaneous vertebroplasty and kyphoplastic for traumatic fracture of thoracolumbar junction. *J Neurosurg Sci*. Mar 2009;53(1):13-17.
33. Coumans JV, Reinhardt MK, Lieberman IH. Kyphoplasty for vertebral compression fractures: 1-year clinical outcomes from a prospective study. *J Neurosurg*. Jul 2003;99(1 Suppl):44-50.
34. Crandall D, Slaughter D, Hankins PJ, Moore C, Jerman J. Acute versus chronic vertebral compression fractures treated with kyphoplasty: Early results. *Spine Journal*. 2004;4(4):418-424.
35. Deen HG, Aranda-Michel J, Reimer R, Miller DA, Putzke JD. Balloon kyphoplasty for vertebral compression fractures in solid organ transplant recipients: results of treatment

- and comparison with primary osteoporotic vertebral compression fractures. *Spine Journal*. 2006;6(5):494-499.
36. Deen HG, Aranda-Michel J, Reimer R, Putzke JD. Preliminary results of balloon kyphoplasty for vertebral compression fractures in organ transplant recipients. *Neurosurgical focus [electronic resource]*. 2005;18(3):e6.
  37. Deen HG, Nottmeier EW. Balloon kyphoplasty for treatment of sacral insufficiency fractures. Report of three cases. *Neurosurg Focus*. Mar 15 2005;18(3):e7.
  38. Dudeney S, Lieberman IH, Reinhardt MK, Hussein M. Kyphoplasty in the treatment of osteolytic vertebral compression fractures as a result of multiple myeloma. *J Clin Oncol*. May 1 2002;20(9):2382-2387.
  39. Feltes C, Fountas KN, Machinis T, et al. Immediate and early postoperative pain relief after kyphoplasty without significant restoration of vertebral body height in acute osteoporotic vertebral fractures. *Neurosurgical focus [electronic resource]*. 2005;18(3):e5.
  40. Gaitanis IN, Hadjipavlou AG, Katonis PG, Tzermiadianos MN, Pasku DS, Patwardhan AG. Balloon kyphoplasty for the treatment of pathological vertebral compressive fractures. *European Spine Journal*. 2005;14(3):250-260.
  41. Garfin SR, Buckley RA, Ledlie J. Balloon kyphoplasty for symptomatic vertebral body compression fractures results in rapid, significant, and sustained improvements in back pain, function, and quality of life for elderly patients. *Spine*. 2006;31(19):2213-2220.
  42. Gerszten PC, Germanwala A, Burton SA, Welch WC, Ozhasoglu C, Vogel WJ. Combination kyphoplasty and spinal radiosurgery: a new treatment paradigm for pathological fractures. *Neurosurgical focus [electronic resource]*. 2005;18(3):e8.
  43. Grohs JG, Matzner M, Trieb K, Krepler P. Treatment of intravertebral pseudarthroses by balloon kyphoplasty. *Journal of Spinal Disorders and Techniques*. 2006;19(8):560-565.
  44. Korovessis P, Hadjipavlou A, Repantis T. Minimal invasive short posterior instrumentation plus balloon kyphoplasty with calcium phosphate for burst and severe compression lumbar fractures. *Spine*. 2008;33(6):658-667.
  45. Korovessis P, Repantis T, Petsinis G, Iliopoulos P, Hadjipavlou A. Direct reduction of thoracolumbar burst fractures by means of balloon kyphoplasty with calcium phosphate and stabilization with pedicle-screw instrumentation and fusion. *Spine*. Feb 15 2008;33(4):E100-108.
  46. Korovessis P, Zacharatos S, Repantis T, Michael A, Karachalios D. Evolution of bone mineral density after percutaneous kyphoplasty in fresh osteoporotic vertebral body

- fractures and adjacent vertebrae along with sagittal spine alignment. *Journal of spinal disorders & techniques*. 2008;21(4):293-298.
47. Ledlie JT, Renfro M. Balloon kyphoplasty: one-year outcomes in vertebral body height restoration, chronic pain, and activity levels. *J Neurosurg*. Jan 2003;98(1 Suppl):36-42.
  48. Ledlie JT, Renfro MB. Decreases in the number and severity of morphometrically defined vertebral deformities after kyphoplasty. *Neurosurgical focus [electronic resource]*. 2005;18(3):e4.
  49. Lee SB, Cho KS, Huh PW, et al. Clinical and radiographic results of unilateral transpedicular balloon kyphoplasty for the treatment of osteoporotic vertebral compression fractures. *Acta neurochirurgica. Supplement*. 2008;101(-):157-160.
  50. Lieberman IH, Dudeney S, Reinhardt MK, Bell G. Initial outcome and efficacy of "kyphoplasty" in the treatment of painful osteoporotic vertebral compression fractures. *Spine*. Jul 15 2001;26(14):1631-1638.
  51. Machinis TG, Fountas KN, Feltes CH, Johnston KW, Robinson JS. Pain outcome and vertebral body height restoration in patients undergoing kyphoplasty. *South Med J*. May 2006;99(5):457-460.
  52. Maestretti G, Cremer C, Otten P, Jakob RP. Prospective study of standalone balloon kyphoplasty with calcium phosphate cement augmentation in traumatic fractures. *European Spine Journal*. 2007;16(5):601-610.
  53. Majd ME, Farley S, Holt R. Preliminary outcomes and efficacy of the first 360 consecutive kyphoplasties for the treatment of painful osteoporotic vertebral compression fractures. *Spine Journal*. 2005;5(3):244-255.
  54. Marco RA, Kushwaha VP. Thoracolumbar burst fractures treated with posterior decompression and pedicle screw instrumentation supplemented with balloon-assisted vertebroplasty and calcium phosphate reconstruction. *J Bone Joint Surg Am*. Jan 2009;91(1):20-28.
  55. Masala S, Cesaroni A, Sergiacomi G, et al. Percutaneous kyphoplasty: new treatment for painful vertebral body fractures. *In Vivo*. Mar-Apr 2004;18(2):149-153.
  56. Masala S, Fiori R, Massari F, Cantonetti M, Postorino M, Simonetti G. Percutaneous kyphoplasty: Indications and technique in the treatment of vertebral fractures from myeloma. *Tumori*. 2004;90(1):22-26.
  57. Masala S, Fiori R, Massari F, Simonetti G. Kyphoplasty: Indications, contraindications and technique. *Radiologia Medica*. 2005;110(1-2):97-105.

58. McArthur N, Kasperk C, Baier M, et al. 1150 kyphoplasties over 7 years: indications, techniques, and intraoperative complications. *Orthopedics*. Feb 2009;32(2).
59. Moon ES, Kim HS, Park JO, et al. The incidence of new vertebral compression fractures in women after kyphoplasty and factors involved. *Yonsei Medical Journal*. 2007;48(4):645-652.
60. Muto M, Perrotta V, Guarnieri G, et al. Vertebroplasty and kyphoplasty: friends or foes? *Radiol Med*. Dec 2008;113(8):1171-1184.
61. Pflugmacher R, Agarwal A, Kandziora F, C KK. Balloon kyphoplasty combined with posterior instrumentation for the treatment of burst fractures of the spine--1-year results. *J Orthop Trauma*. Feb 2009;23(2):126-131.
62. Pflugmacher R, Beth P, Schroeder RJ, Schaser KD, Melcher I. Balloon kyphoplasty for the treatment of pathological fractures in the thoracic and lumbar spine caused by metastasis: one-year follow-up. *Acta radiologica (Stockholm, Sweden : 1987)*. 2007;48(1):89-95.
63. Pflugmacher R, Kandziora F, Schroeder RJ, Melcher I, Haas NP, Klostermann CK. Percutaneous balloon kyphoplasty in the treatment of pathological vertebral body fracture and deformity in multiple myeloma: a one-year follow-up. *Acta radiologica (Stockholm, Sweden : 1987)*. 2006;47(4):369-376.
64. Pflugmacher R, Schroeder RJ, Klostermann CK. Incidence of adjacent vertebral fractures in patients treated with balloon kyphoplasty: two years' prospective follow-up. *Acta Radiol*. Oct 2006;47(8):830-840.
65. Pflugmacher R, Taylor R, Agarwal A, et al. Balloon kyphoplasty in the treatment of metastatic disease of the spine: a 2-year prospective evaluation. *Eur Spine J*. Aug 2008;17(8):1042-1048.
66. Phillips FM, Ho E, Campbell-Hupp M, McNally T, Todd Wetzell F, Gupta P. Early radiographic and clinical results of balloon kyphoplasty for the treatment of osteoporotic vertebral compression fractures. *Spine*. Oct 1 2003;28(19):2260-2265; discussion 2265-2267.
67. Rhyne A, 3rd, Banit D, Laxer E, Odum S, Nussman D. Kyphoplasty: report of eighty-two thoracolumbar osteoporotic vertebral fractures. *J Orthop Trauma*. May-Jun 2004;18(5):294-299.
68. Robinson Y, Tschoke SK, Stahel PF, Kayser R, Heyde CE. Complications and safety aspects of kyphoplasty for osteoporotic vertebral fractures: a prospective follow-up study in 102 consecutive patients. *Patient Saf Surg*. 2008;2:2.

69. Ryu KS, Park CK, Kim MK, Kim DH. Single balloon kyphoplasty using far-lateral extrapedicular approach: technical note and preliminary results. *J Spinal Disord Tech*. Jul 2007;20(5):392-398.
70. Stoffel M, Wolf I, Ringel F, Stuer C, Urbach H, Meyer B. Treatment of painful osteoporotic compression and burst fractures using kyphoplasty: A prospective observational design. *Journal of Neurosurgery: Spine*. 2007;6(4):313-319.
71. Voggenreiter G. Balloon kyphoplasty is effective in deformity correction of osteoporotic vertebral compression fractures. *Spine*. 2005;30(24):2806-2812.
72. Yang HL, Wang GL, Niu GQ, et al. Using MRI to determine painful vertebrae to be treated by kyphoplasty in multiple-level vertebral compression fractures: a prospective study. *J Int Med Res*. Sep-Oct 2008;36(5):1056-1063.
73. Zhang Q, Zou DW, Hai Y, Ma HS, Bai KW. Balloon kyphoplasty: An experience of 38 patients with painful osteoporotic vertebral compressive fractures. *Chinese Journal of Traumatology - English Edition*. 2006;9(4):206-210.
74. Jenkinson C. The SF-36 physical and mental health summary measures: an example of how to interpret scores. *J Health Serv Res Policy*. April 1998;3(2):92-96.
75. Jaeschke R, Singer J, Guyatt GH. Measurement of health status. Ascertaining the minimal clinically important difference. *Control Clin Trials*. Dec 1989;10(4):407-415.
76. Prather H, Hunt D, Watson JO, Gilula LA. Conservative care for patients with osteoporotic vertebral compression fractures. *Phys Med Rehabil Clin N Am*. Aug 2007;18(3):577-591, xi.
77. Kim YJ, Lee JW, Park KW, et al. Pulmonary cement embolism after percutaneous vertebroplasty in osteoporotic vertebral compression fractures: incidence, characteristics, and risk factors. *Radiology*. Apr 2009;251(1):250-259.

## SEARCH STRATEGIES

### PubMed

- [#17](#) Search (#14 NOT #15) OR #16
- [#16](#) Search #15 AND (SYSTEMATIC\* OR TRIAL OR TRIALS OR RANDOM\* OR CONTROLLED)
- [#15](#) Search #14 AND REVIEW[PT]
- [#14](#) Search #12 NOT #13
- [#13](#) Search #12 AND (CEMENT[TI] OR BIOMECHAN\*[TI] OR MECHAN\*[TI])
- [#12](#) Search #10 NOT #11
- [#11](#) Search #10 AND CADAVER\*
- [#10](#) Search #5 OR #6 OR #7 OR #8 OR #9
- [#9](#) Search #4 AND COMPARATIVE STUDY[PT]
- [#8](#) Search #4 AND TREATMENT OUTCOME[MH] AND (CLINICAL TRIAL[PT] OR MULTICENTER STUDY[PT] OR VALIDATION STUDIES[PT] OR EVALUATION STUDIES[PT] OR LONGITUDINAL STUDIES[MH] OR FOLLOW-UP STUDIES[MH] OR EFFICAC\* OR EFFECTIVE\*)
- [#7](#) Search #4 Limits: Meta-Analysis, Research Support, N I H, Extramural, Research Support, N I H, Intramural, Research Support, Non U S Gov't, Research Support, U S Gov't, Non P H S, Research Support, U S Gov't, P H S
- [#6](#) Search #4 AND OBSERVATIONAL[TIAB]
- [#5](#) Search #4 AND (RANDOMIZED CONTROLLED TRIAL[PT] OR CONTROLLED CLINICAL TRIAL[PT] OR RANDOMIZ\* OR RANDOMIS\* OR RANDOMLY OR RANDOM[TIAB])
- [#4](#) Search #3 AND ENG[LA]
- [#3](#) Search #1 AND #2
- [#2](#) Search SPINAL FRACTURES[MH] OR (SPINAL INJURIES[MH:NOEXP] AND FRACTURES[MH:NOEXP]) OR FRACTURES, COMPRESSION[MH] OR (FRACTURES, BONE[MH] AND (SPINE OR SPINAL OR VERTEBR\*)) OR VERTEBRAL COMPRESS\*
- [#1](#) Search VERTEBROPLASTY[MAJR] OR KYPHOPLAST\*

**Duplicated above search, but include:** CEMENT[TI] OR BIOMECHAN\*[TI] OR MECHAN\*[TI]

**Also searched:** KYPHOPLAST\*[TI] AND (IN PROCESS[SB] OR PUBLISHER[SB] OR PUBMEDNOTMEDLINE[SB]) AND ENG[LA]

### Embase

- [#1](#) 'kyphoplasty'/de OR 'kyphoplasty' OR 'kyphoplasties'
- [#2](#) #1 AND [english]/lim
- [#3](#) #2 AND ([cochrane review]/lim OR [controlled clinical trial]/lim OR [meta analysis]/lim OR [randomized controlled trial]/lim OR [systematic review]/lim)
- [#4](#) #2 AND ('controlled study'/de OR 'controlled clinical trial'/exp OR 'observational study'/de OR 'multicenter studies'/de OR 'randomization'/de OR 'clinical study'/de)
- [#5](#) #2 AND (observational:ti,ab OR 'observation study':ti,ab OR 'observation studies':ti,ab OR random\*)
- [#6](#) #3 OR #4 OR #5
- [#7](#) #6 NOT cadaver\*

### Cochrane

- [#1](#) [\(kyphoplast\\*\)](#)